

## New treatment of lameness

English Translation of original article in German »Neue Behandlung bei Lahmheiten - Schwachpunkt Fesselträger« in Reiter Revue International 02/2011, p. 84-86

## SUSPENSORY LIGAMENT – THE ULTIMATE POINT OF VULNERABILITY

Injuries to the musculus interosseus medius, ligaments and tendons are likely to unleash an avalanche of relapse diseases. The combination of an autologous conditioned blood therapy with shock wave application offers a new way of healing with favourable prognosis. Here is a field report of equine veterinary specialist Dr. Mark Kaminski.

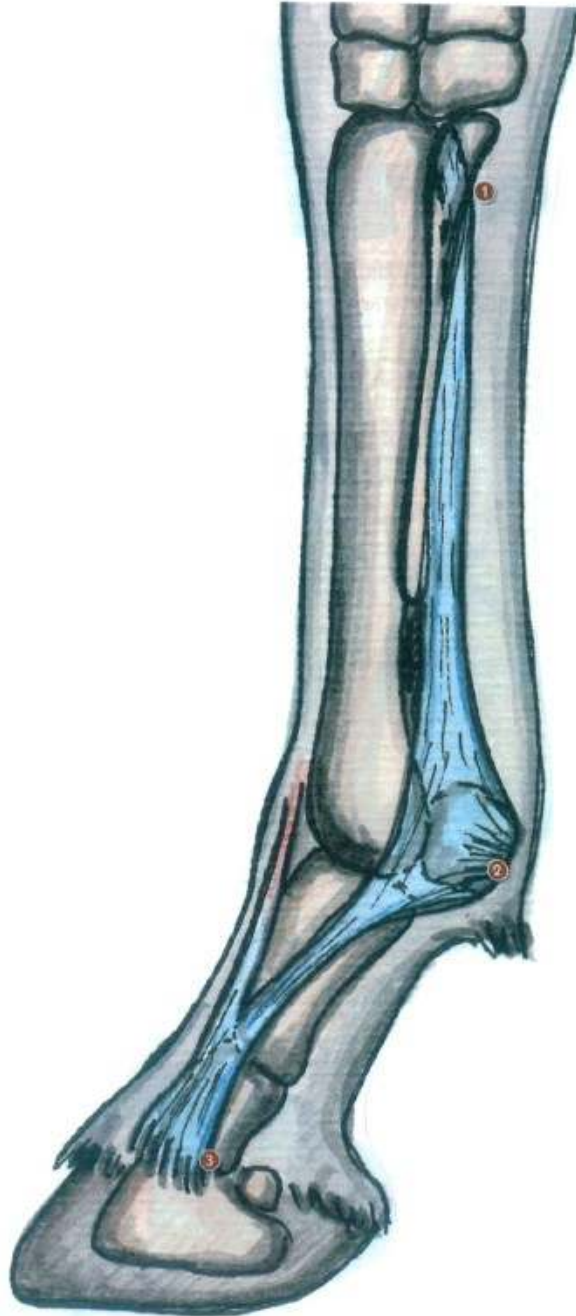
Almost every day, horses with unspecified lameness and locomotor disorders are being examined in numerous equine orthopaedic surgeries all over Germany. "In most cases, young horses with particularly strong movements are concerned that perfectly reflect today's breeding goals for sport horses", reports FEI veterinarian Dr. Mark Kaminski. The veterinary specialist in equine orthopaedics at the equine surgery in Bochum summarizes the riders' reports: "For a while, the horse has suffered from blockades when turning and exhibited gait abnormalities. After a few days of rest, the horse movements improve, however with increasing exercise, the problems get worse again."

### Risk of chronic lameness

Even if no injury can be detected from the outside, the ligaments, tendons and the suspensory ligament inside the horse's leg are often affected. "The suspensory ligament is the most important functional element of the suspensory apparatus of the fetlock", explains the veterinary specialist. "It is subjected to all tensile stress produced by the lower limbs."

According to a recent study performed by Vienna University, suspensory ligament disorders are currently the most frequent orthopaedic disease pattern in dressage and eventing sports and the second most common problem of jumpers, that lead to chronic lameness and – to an ever-increasing extent – even to complete unsuitability for horse shows. This type of orthopaedic disorder frequently affects young horses of up to 8 years of age, in particular.

Most of the conventional treatment methods applied up to now turned out to be more or less promising. "The combined treatment with specially conditioned autologous blood and shock waves could open up new ways of healing", explains Kaminski. Though he also emphasizes that, due to the poor blood circulation in tendon-type collagen fibres, long-term healing processes are generally to be expected. The therapies are aimed at enhancing the blood circulation and thus increasing the cell generation. As compared to the original tissue, the newly generated substitution tissue is based on another collagen type (Editor's note: a different structural protein of the connective tissue). This tissue exhibits lower strength and elasticity and is thus more injury-prone. This is why a correct orientation of the substitution tissue must be ensured during therapy in order to maintain maximum elasticity. Many injuries occur at the bony insertion points, for example at the suspensory ligament origin on the rear side of the cannon bone or at the sesamoid bones, where the suspensory ligament branches originate. "As, unlike the flexor tendons, the suspensory ligament fibres originate from a bone and not from a muscle, they are subjected to substantially higher stress. And a bone cannot be stretched like a muscle", comments the FEI veterinarian. For this reason, the therapy must ensure proper connection of the individual fibres at the bone surface to give sufficient stability even under stress.



**1.** The suspensory ligament origin at the rear side of the cannon bone is often affected by injuries. **2.** The fetlock annular ligament covers the flexor tendons in the area of the fetlock. **3.** The suspensory ligament ends as ramification together with the extensor tendon in the coffin bone.

### Detected in aircraft construction

According to Kaminski, a combination of two essential therapy types has been developed over the past years: The autologous blood treatment with repeated shock and pressure wave application. The therapy is started with the blood treatment (see info box on page 86 for more details) to enhance the renewal of the cell structures. Depending on the severity of the injury, the injection is repeated. "Approximately two weeks later, we begin with the shock and/or pressure wave treatment", declares Kaminski. "These mechanical waves are subdivided into extracorporeal shock waves and radial pressure waves." About twelve years ago, this type of therapy was applied for the first time in equine orthopaedics.

After having been detected by chance in aeronautics during the jet wing development, this wave type was initially used in human medicine for the disintegration of kidney stones. The therapeutic impact of acoustic waves on orthopaedic disorders was only detected afterwards.

### Young horses over(s)trained?

The type of wave to be used in the different treatment regions depends on the location of the injury. There are, however, certain overlaps of the fields of application, confirms Dr. Kaminski. This is due to the fact, that "the new generation of pressure and shock wave generator systems features fine adjustment of strength, frequency, penetration depth and wave type, so that these parameters are freely selectable." But what exactly happens when the waves are applied to a horse leg? "In the end, shock waves enhance blood circulation in the tissue, activate the growth factors and disintegrate agglutination caused by the scarred healing of the tissue", explains the expert.

Depending on the severity of the injury, shock waves are applied between three and five times at intervals of 14 to 21 days. "In addition, the equine patient is subjected to a matched exercise therapy and individual follow-up examinations, while the question of suitable therapeutic shoes for the recovery period is discussed with the blacksmith." As a matter of course, there are also chronic forms of tendon and ligament injuries that cannot be healed by the combined therapy. This is why focus is placed on efficient diagnostics in Bochum. "It is of prior importance to check whether the combined therapy is actually indicated for the treatment of a specific injury." In addition to the assessment carried out while the horse is moving on hard and soft ground in a straight line and in turns – if necessary, also while being ridden – the leg concerned is anaesthetized and further diagnostic imaging is performed. For this purpose, mainly ultrasound systems, but also X-ray, computer tomography and magnetic resonance imaging are applied.

According to the FEI veterinarian, the question should be asked why these causes of lameness are observed to an increasing extent. "Breeding of today's multipurpose horse is focussed above all on rideability and elasticity. This is why these horses are able to meet high demands at very young age. However, at this stage, the length growth of the cannon bones is not yet completed, which causes substantial tensile stress on the suspensory apparatus." The suspensory ligament is affected in particular as it is directly subjected to the tensile strain produced by the cannon bone. The presence of a still "soft muscular connection" of the suspensory ligament structure to the cannon bone was disproved, as an identical muscle fibre share was found in

### VITA

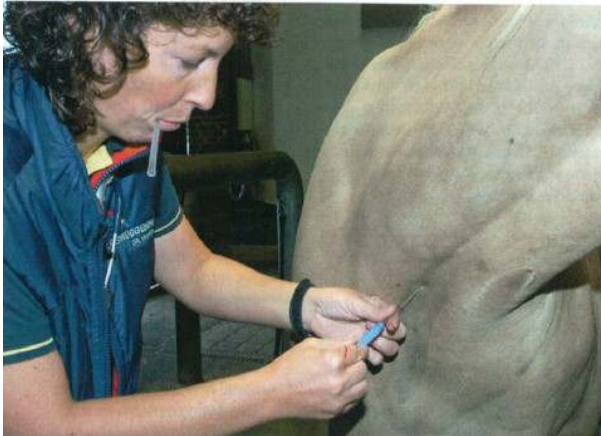Dr. med. vet. Mark Kaminski



Born in Essen in 1970, Mark Kaminski studied veterinary medicine in Gießen and worked as assistant doctor in equine clinics in Munich and Stuttgart, where he specialized in equine medicine and equine orthopaedics. Today, the FEI veterinarian is head of the equine surgery in Bochum and specialized in rideability problems and veterinary sport horse attendance. In addition, Kaminski is a contract veterinarian of the Hanoverian society.

adult horses. Against this background, Dr. Kaminski raises serious concerns: "Considering the high demands made on young horses in terms of early breaking-in and training as well as frequent participation in horse shows, we should ask ourselves if these exacting requirements are not simply exaggerated."

Therapy forms



First of all, blood samples are taken from the horse, certain components of which are subsequently conditioned. The resulting autologous conditioned plasma with cell growth factors is then directly injected into the musculus interosseus medius, tendons or ligaments.



Originally used for kidney stone disintegration, shock wave therapy has made its way into equine orthopaedics.

**Autologous blood therapy**

In medicine, the term "autologous" is used when donor and recipient in transplantations are identical. However, an autologous blood therapy is not an autohaemotherapy in the classical meaning. Only parts of the blood are treated to obtain the autologous conditioned plasma that is then injected into the affected area, i.e. in tendons, ligaments or the suspensory ligament of the fetlock. "This plasma contains the growth factors linked to thrombocytes, which are generally considered as being decisive for the recovery of the damage", describes Dr. Kaminski the background of the treatment. In general, the therapy is started only after the acute symptoms have ceased and repeated, if necessary. It is only two weeks after the autologous blood therapy that the shock wave treatment is started.

**Extracorporeal shock wave therapy**

With conventional extracorporeal shock wave systems, the waves are produced by an electromagnetic generator and then reflected by a reflector – referred to as parabolic mirror in the technical terminology – before being focussed in a point deep in the tissue. As the impact of this high-energy wave is limited to an area of a few millimetres only and the wave should be preferably directed on a solid surface, it is mainly used for the treatment of deep-seated calcifications or deep injuries at the suspensory ligament origin, for instance. The term "extracorporeal" refers to the fact that the shock waves are generated outside the body. The treatment is painful for the horse if the waves are targeted directly on the bone skin. This is why Dr. Mark Kaminski generally recommends previous anaesthetization of the equine patient. A shock wave therapy session usually takes about ten minutes.

**Radial pressure wave therapy**

With radial pressure waves the maximum energy is generated at the skin surface, while the wave propagates radially over a large area. The term "radial" refers to the fact that the wave is "not focussed". Radial pressure waves can thus not be used for precisely targeted application. Unlike shock waves, pressure waves have a much lower penetration depth. This is why this wave type is used for all disorders affecting the tendon and ligament apparatus, but also for the treatment of injuries to the muscle tissue. In general, pressure wave treatment causes only minor pain. In most cases, the equine patient easily accepts the ten-minute treatment with both, shock and pressure waves after a relatively short time. However, the noise produced by the system may cause some trouble at the beginning of the therapy. For this reason, it is generally recommended to administer a sedative before starting a shock or pressure wave therapy session.